

## 4. Dyspnea

**Case scenario:**

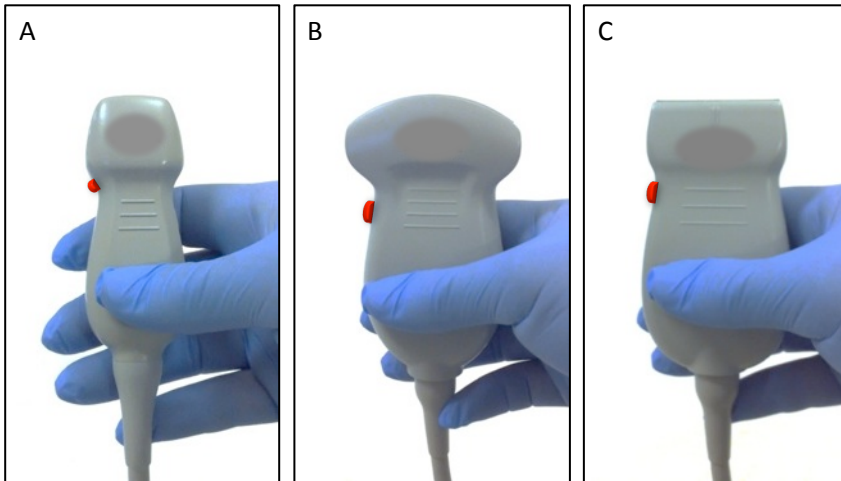
A 70 year-old woman presents herself to your clinic complaining of dyspnea. She is too short of breath to provide a useful history. Her respiratory rate is 40 breaths/min, her oxygen saturation is 80%, and she is tachycardic with normal blood pressure. On auscultation, there is poor air entry bilaterally.

**Impression: Dyspnea NYD. Consider common causes.**

Common causes of **dyspnea** can be recognized by ultrasound examination of the chest. This chapter reviews the technique for diagnosis of pneumothorax, interpretation of lung artifacts, and identification of pleural effusions.

## 4.1. Probe choice

Both low and high frequency probes can be used for this application.



**Figure 4.1** Low and high frequency probes that can be used for assessing the patient with dyspnea.

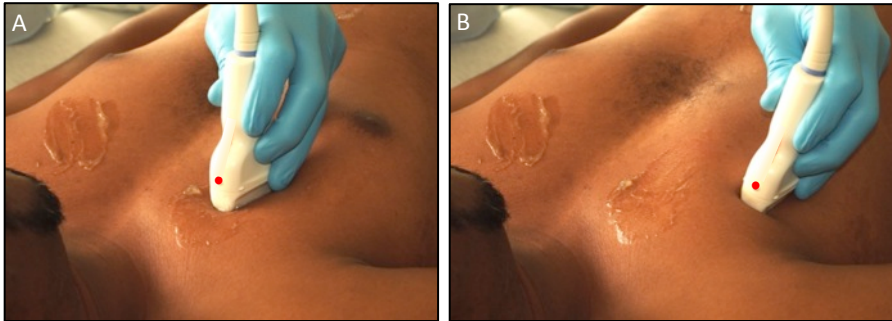
**A.** A low frequency phased array probe.

**B.** A low frequency curvilinear probe.

**C.** A high frequency linear probe. Red circle denotes orientation marker.

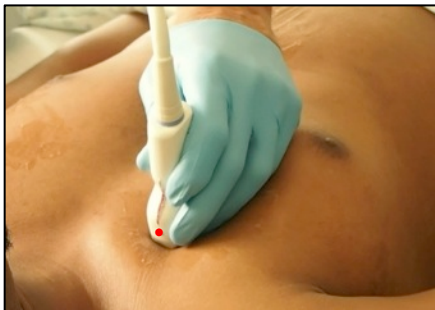## 4.2. Patient position and scanning technique

The patient should lie supine or be semi-seated in bed. Scan the anterior chest in the second to third rib interspace in the mid-clavicular line and the fourth to fifth rib interspace in the anterior axillary line.



**Figure 4.2 Scanning technique for imaging the anterior chest.**

The anterior chest is imaged bilaterally with a linear probe in the mid-clavicular line **(A)** and anterior axillary line **(B)**. The orientation marker points cephalad. Red circle denotes orientation marker.



**Video 4.1 Scanning technique with lateral rocking motion.**

The lateral rocking motion of the probe improves the sensitivity for locating pathology (Lichtenstein, 2010). Red circle denotes orientation marker. View video online at [bedsideultrasoundlevel1.com](http://bedsideultrasoundlevel1.com)

### 4.3. Lung sliding

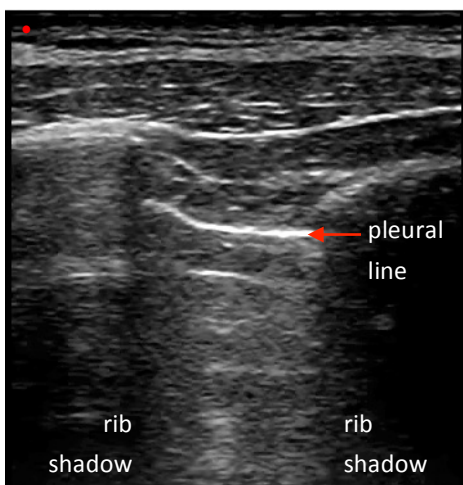
During respiration, the parietal and visceral pleura slide over one another. This horizontal pleural movement during respiration is observed on an ultrasound image and is called **lung sliding** (Lichtenstein et al., 1995).

#### Characteristics of lung sliding

- The area deep to the pleural line sways side-to-side with the patient's breathing
- The hyperechoic (white) pleural line moves or 'shimmers'

#### Clinical relevance of lung sliding – Pneumothorax

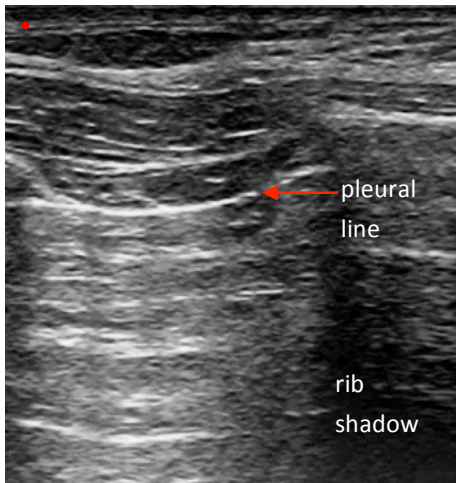
A pneumothorax is a collection of air between the parietal and visceral pleura. Air in the pleural space prevents the contact between the pleurae and therefore prevents lung sliding. In all cases of pneumothorax, lung sliding will be absent in the scanned area over the anterior chest of a supine patient. Therefore normal lung sliding confidently rules out pneumothorax (Kirkpatrick et al., 2004; Lichtenstein et al., 2005; Noble et al., 2007; Piette et al., 2013).



#### ***Video 4.2 Presence of lung sliding on the anterior chest using a linear probe.***

*The hyperechoic (white) pleural line 'shimmers', thus illustrating lung sliding. Accordingly, this patient does not have a pneumothorax. Red circle denotes orientation marker. View video online at [bedsideultrasoundlevel1.com](http://bedsideultrasoundlevel1.com)*

Importantly, the absence of lung sliding **suggests but is not specific** for a pneumothorax because there are other conditions in which lung sliding is absent or hard to detect. These conditions include pleural adhesions, atelectasis, apnea, unilateral bronchial intubation, and extremely shallow rapid breathing (asthma) (Lichtenstein, 2010).

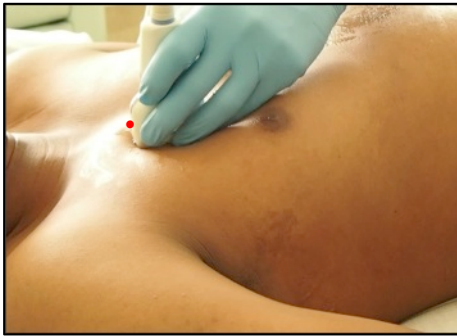


**Video 4.3 Absence of lung sliding on the anterior chest using a linear probe.**

*Note that the pleural line does not 'shimmer' or slide laterally. Therefore, this patient may have a pneumothorax. Red circle denotes orientation marker. View video online at [bedsideultrasoundlevel1.com](http://bedsideultrasoundlevel1.com)*

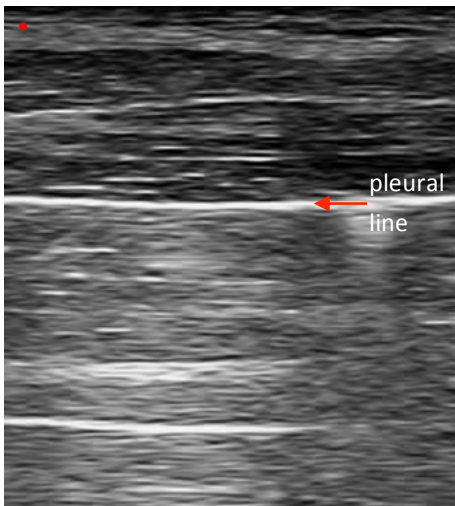
When the absence of lung sliding is observed, a pneumothorax can be confirmed by detecting a **lung point**. The lung point is an ultrasound landmark specific for a pneumothorax (Lichtenstein et al., 2000).

To look for a lung point, start scanning the anterior chest of a supine patient in whom you have detected the absence of lung sliding. Gradually scan over the chest posterolaterally. A lung point is defined by the alternating presence and absence of lung sliding between two ribs as the patient breathes. The lung point corresponds to that area over the chest wall where the partially deflated lung moves into the ultrasound field of view during inspiration and then out again during expiration.



**Video 4.4 Scanning technique for imaging a lung point using a linear probe.**

*Red circle denotes orientation marker. View video online at [bedsideultrasoundlevel1.com](http://bedsideultrasoundlevel1.com)*



**Video 4.5 Lung point on posterolateral chest using linear probe.**

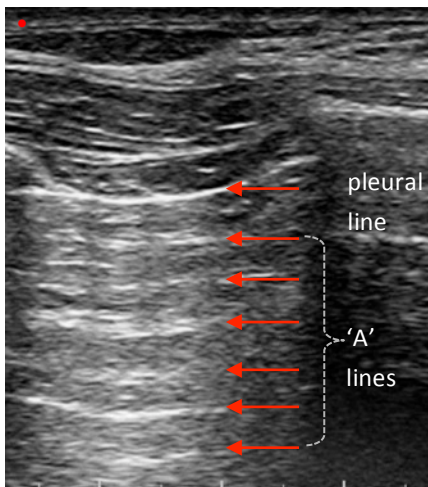
*Note the lung sliding coming and going from the right of the screen. Red circle denotes orientation marker. View video online at [bedsideultrasoundlevel1.com](http://bedsideultrasoundlevel1.com)*

#### 4.4. 'A' lines

An **'A' line** artifact is a hyperechoic (white) horizontal line arising at regular intervals from the pleural line. An 'A' line artifact is produced when scanning the anterior chest of a patient with normal lungs or in a patient with diseased lungs without interstitial disease (e.g. obstructive airways disease) (Lichtenstein, 2010).

##### Characteristics of 'A' lines

- Horizontal hyperechoic (white) lines
- Evenly spaced throughout the ultrasound field
- Immobile



**Figure 4.3 'A' lines in a normal lung.**

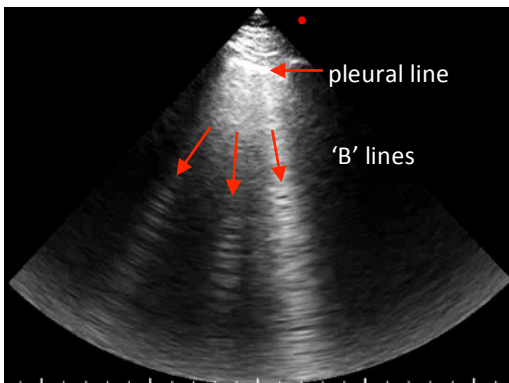
*Anterior chest scan with a linear probe. Red circle denotes orientation marker.*

## 4.5. 'B' lines

A '**B**' line artifact is a hyperechoic (white) vertical line arising from the pleural line. A '**B**' line is a non-specific artifact produced with any disease of the pulmonary interstitium including pneumonia, pulmonary edema, interstitial fibrosis, and acute respiratory distress syndrome. Three or more '**B**' lines between two rib shadows are considered abnormal (Lichtenstein et al., 1998).

### Characteristics of 'B' lines

- Vertical, comet-shaped hyperechoic (white) lines
- Originate at the pleura and extend to the far-field of the ultrasound screen
- Move with the pleura
- Eliminate 'A' lines



### **Video 4.6. 'B' lines in a diseased lung.**

*Anterior chest scan (with a phased array probe in the cardiac setting) displaying vertical 'B' lines that originate at the pleura and extend to the far-field. Red circle denotes orientation marker. View video online at [bedsideultrasoundlevel1.com](http://bedsideultrasoundlevel1.com)*



## 4.6. Lung profiles

### Clinical relevance of 'A' lines - 'A' profile

If you see lung sliding with 'A' lines on bilateral anterior chest exams, the patient is defined as having an **'A' profile**. Patients presenting with an 'A' profile and dyspnea generally have chronic obstructive pulmonary disease (COPD) or asthma exacerbation. Patients with an 'A' profile, dyspnea, and a deep venous thrombosis (DVT) are likely to have a pulmonary embolism (Lichtenstein et al., 2008).

### Clinical relevance of 'B' lines - 'B' profile

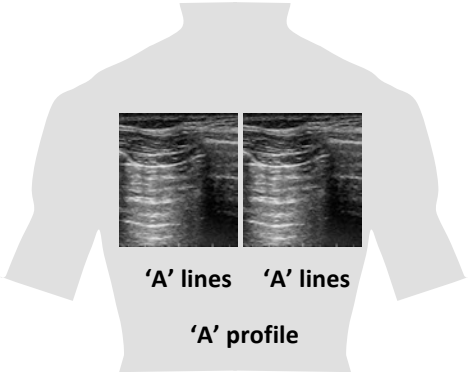
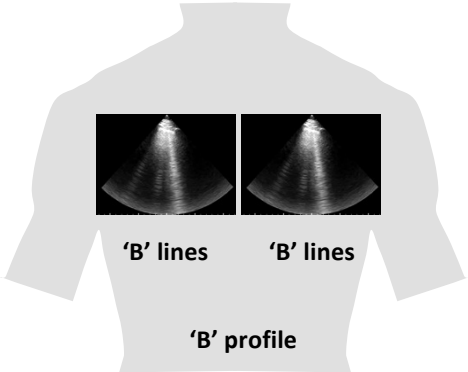
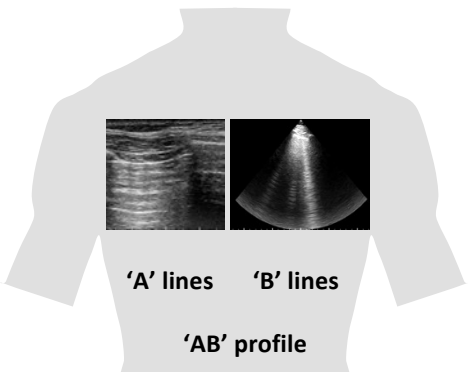
If you see lung sliding with 'B' lines on bilateral anterior chest scans, the patient is defined as having a **'B' profile**. Dyspneic patients presenting to the emergency room with a 'B' profile generally have cardiogenic pulmonary edema (Lichtenstein and Meziere, 2008).

However, the interpretation of lung profiles must always be done in context of the clinical impression. For example, a patient presenting with a 'B' profile in association with fever, rigors, cough, and productive sputum, likely has bilateral pneumonia and not cardiogenic pulmonary edema.

### Clinical relevance of 'A' + 'B' lines - 'AB' profile

If one side of the anterior chest has 'A' lines while the other side has 'B' lines the patient is said to have an **'AB' profile**. Patients presenting with an 'AB' profile and dyspnea are likely to have pneumonia as the cause of their dyspnea (Lichtenstein and Meziere, 2008).

**Table 4.1 Lung profiles and common associated pathologies in outpatients presenting with dyspnea.**

Lung profile	Pathology
 <p>'A' lines    'A' lines</p> <p>'A' profile</p>	<p><b>COPD</b></p> <p><b>Asthma</b></p> <p><b>Pulmonary embolism</b> (if DVT present)</p>
 <p>'B' lines    'B' lines</p> <p>'B' profile</p>	<p><b>Cardiogenic pulmonary edema</b></p>
 <p>'A' lines    'B' lines</p> <p>'AB' profile</p>	<p><b>Pneumonia</b></p>

## 4.7. Posterolateral chest

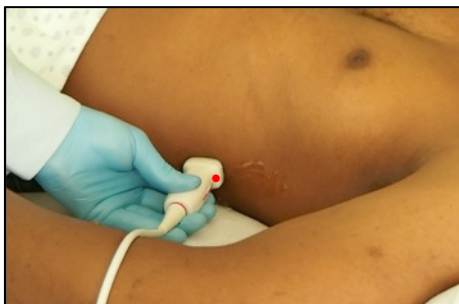The posterolateral chest is examined for pleural effusions and lung consolidation.

### Characteristics of the posterolateral chest exam

- Diaphragm appears as a hyperechoic (white) line, concave caudally
- Normal lung appears as a **'curtain' sign** sweeping into the field as the diaphragm descends
- Pleural effusion appears as an anechoic (black) area above the diaphragm
- Lung consolidation appears as a hypoechoic (grey) structure above the diaphragm

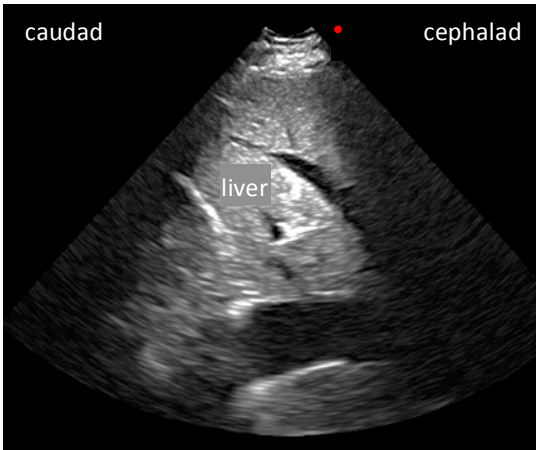
### Clinical relevance - Posterolateral chest exam

- Patients with dyspnea, a normal anterior chest exam (bilateral 'A' lines), no DVT, and an unilateral pleural effusion or consolidation, likely have pneumonia (Lichtenstein and Meziere, 2008)
- Patients with left ventricular dysfunction, a 'B' profile, and bilateral pleural effusions likely have congestive heart failure (Lichtenstein and Meziere, 2008)
- Pleural effusions with hyperechoic (white) floating particles or septae are likely to be exudative (Yang et al., 1992)
- Ultrasound can be used to safely guide a thoracentesis (Barnes et al., 2005; Jones et al., 2003)



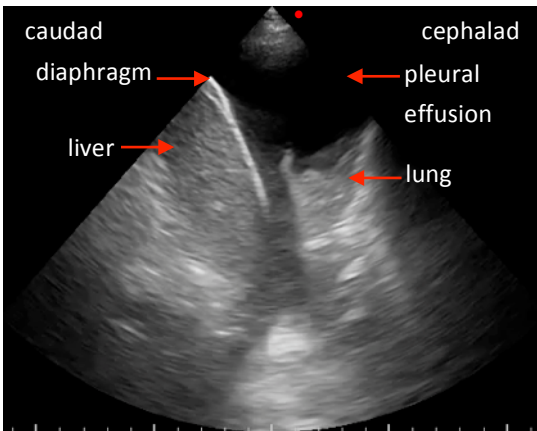
***Video 4.7 Scanning technique for imaging a pleural effusion or lung consolidation over the left posterolateral chest using a phased array probe.***

*Red circle denotes orientation marker. View video online at [bedsideultrasoundlevel1.com](http://bedsideultrasoundlevel1.com)*



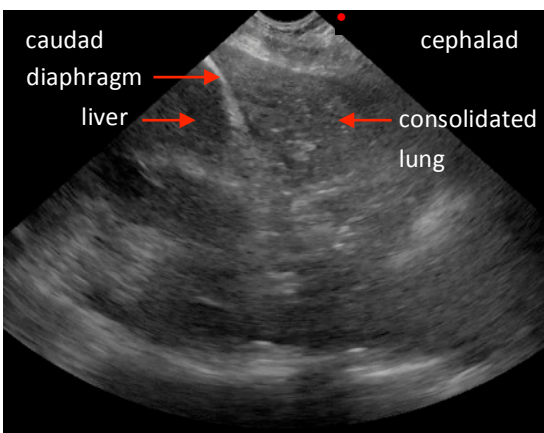
**Video 4.8 Normal lung revealed by a posterolateral chest scan with a phased array probe in the cardiac setting.**

As the diaphragm descends caudally, the lung enters the right-side field of view. This is termed the 'curtain' sign. Red circle denotes orientation marker. View video online at [bedsideultrasoundlevel1.com](http://bedsideultrasoundlevel1.com)



**Video 4.9 Large pleural effusion revealed by a posterolateral chest scan with a phased array probe in the cardiac setting.**

The pleural effusion is cephalad to the diaphragm and appears anechoic (black). Red circle denotes orientation marker. View video online at [bedsideultrasoundlevel1.com](http://bedsideultrasoundlevel1.com)



**Figure 4.4 Lung consolidation revealed by a posterolateral chest scan with a phased array probe in the cardiac setting.**

The consolidated lung is a hypoechoic (grey) structure. Red circle denotes orientation marker.

## 4.8. Troubleshooting tips

- To detect a pneumothorax in a supine patient, be sure to examine the anterior chest. This is because the pneumothorax will accumulate anteriorly.
- Beware that a lung point will not be found in a tension pneumothorax because the lung is completely collapsed in this condition and therefore does not contact the chest wall.
- In cachectic patients with a protruding rib cage, it is difficult to establish adequate contact between a linear probe and the chest wall. This difficulty can be overcome by turning the probe in the transverse plane so that it fits between the ribs, or by using a microconvex probe.
- If lung sliding is difficult to identify with a low frequency probe, use a linear high frequency probe instead.

### Case closed:

The 70 year-old woman who presented herself to your clinic complaining of dyspnea has clinical evidence of congestive heart failure. She is found to have a 'B' profile on lung ultrasound. Diuretic is administered and the patient is hospitalized.